



## Psoas Abscess Due to Appendicitis; Case Report And Review of the Literature

### Apandisite Bağlı Psoas Apsesi: Olgu Sunumu Eşliğinde Literatürün Gözden Geçirilmesi

Apandisite Bağlı Psoas Apsesi / Psoas Abscess due to Appendicitis

Cem Özgür<sup>1</sup>, Asım Özayar<sup>1</sup>, Tarkan Uzun<sup>2</sup>, Yeliz Tuna<sup>3</sup>

<sup>1</sup>Urology Department, Ankara Etlik İhtisas Education Training Hospital, <sup>2</sup>General Surgery Department, Ankara Gazi Mustafa Kemal Hospital, <sup>3</sup>Radiology Department, Ankara Gazi Mustafa Kemal Hospital, Ankara, Turkey

#### Özet

Psoas apsesi nadir görülen ve tanı konmakta genellikle zorlanılan ve geç kalınan bir durumdur. Klasik semptomların sadece bazı hastalarda görülmesi nedeni ile tanısı ve dolayısı ile tedavisi gecikmektedir. Çoğu merkezde tanıda rutin ultrasonografi ve bilgisayarlı tomografi kullanılır. Oldukça nadir görülen bu hastalığın tedavisinde ise drenaj (cerrahi veya perkütan) önerilmektedir. Psoas apsesi apandisite bağlı oluşan, bilgisayarlı tomografi ile tanısı konan ve cerrahi olarak tedavi edilen bir olguyu sunmaktayız.

#### Anahtar Kelimeler

Psoas Apsesi; Apandisit; Tedavi

#### Abstract

Psoas abscess is an uncommon condition and its diagnosis is usually delayed and difficult. Classical symptoms and findings can be seen in very few of the patients so the diagnosis and therefore treatment is usually delayed. In many centers routinely ultrasonography and computerized tomography of abdomen are used for the diagnosis. Combination of antibiotic treatment and drainage (surgical or percutaneous) are recommended in the management of this rarely seen disease. We present a case with psoas abscess rarely seen in our department, caused because of appendicitis, and diagnosed with computerized tomography and treated surgically.

#### Keywords

Psoas Abscess; Appendicitis; Treatment

DOI: 10.4328/JCAM.500

Received: 28.12.2010

Accepted: 14.10.2010

Printed: 01.07.2012

J Clin Anal Med 2012;3(3): 344-6

Corresponding Author: B. Cem Özgür, Etlik İhtisas Hastanesi Üroloji Kliniği, Etlik, Ankara, Türkiye.

T.: +90 312567200/2257 E-Mail: bcemozgur@hotmail.com

**Introduction**

Psoas abscess is a very rare pathologic disorder and its diagnosis and treatment is usually problematic and delayed [1]. In the last few decades the incidence has probably increased because of the developments in radiology. The psoas muscle lies beyond a number of abdominal organs so the infections of these organs may affect this muscle secondarily. Sometimes that abscess is because of an unidentified focus as named primary psoas abscess [2].

**Case Report**

A 53 year old man was hospitalized because of chronic bronchitis at a center near our hospital. He developed a dull ache in the superior posterior thigh and right lower abdomen after a few days of hospitalization. He denied any direct trauma or excessive strenuous activity. On physical examination the patient was afebrile with right hip and abdominal tenderness, pain on motion, and a flexion contracture of nearly 20 degrees. In his right groin there was a suspect palpable mass. Laboratory findings were as follows: Hemoglobin 9.1 g/dL, white blood cell count 11.500/mm<sup>3</sup> with a predominant left shift, erythrocyte sedimentation rate 80 mm/h, C reactive protein 115 mg/dL. Urinalysis was normal and urine cultures yielded no growth. Over four days he developed progressively severe, dull pain, localized to the right lower abdomen and posterior hip. Computed tomography (CT) scan revealed a 3 x 11 x 12 cm fluid collection in the right groin adjacent to the iliopsoas muscle, extending toward the iliac vessels (Picture 1). Broad spectrum antibiotic therapy was started immediately (metranidasole and cephalosporin). Surgery was

done three days after detecting the intraabdominal mass via a paramedian incision, muscle splitting, extra-peritoneally, the muscle was first aspirated then incised and nearly 200 ml of purulent material which grew enteric flora was drained. Intraoperatively it was seen that appendix was inflamed and appendectomy was also performed. The abscess margins were bordered with the caecum, and dissected carefully in order to avoid damage to the intestinal system. A large drain was inserted into the incised portion of the right psoas muscle and fixed to the skin via a separate incision. Postoperatively, the patient improved dramatically and no post-operative period problem was occurred. The drain was removed after 10 days. The empirical treatment, was changed to a more custom-tailored treatment that is directed at the causative bacterium and continued for two weeks. After fifteen days follow up CT showed substantial reduction of the size of the collection. Multiple control blood and urine cultures were negative.

**Discussion**

The psoas muscle is a retroperitoneal muscle that originates from the lateral borders of the 12th thoracic to fifth lumbar vertebrae and inserts in the trochanter of the femur. This muscle lies proximal to many other organs, including the caecum, jejunum, appendix, ureters, aorta, renal pelvis, sigmoid colon, pancreas, iliac lymph nodes, and spine. Thus, infections in these organs can affect the psoas muscle and named as secondary abscess (Table 1). The arterial supply of the psoas muscle is very rich that results hematogenous spread from different organs [3]. In our patient because of an inflamed appendix the abscess of the psoas muscle occurred and appendectomy was performed synchronously.

Staphylococcus aureus is the pathogen in three fourth of cases of primary psoas abscess while E coli and some streptococcus and enterobacter species are the main causes of secondary psoas abscess [4,5]. The number of cases because of Mycobacterium tuberculosis is decreasing especially in the last years because of the improvements of not only health conditions but also treatment strategies, but it must always be in mind that tuberculosis is still an important reason of psoas abscess especially in the developing countries [6]. With the early and specific treatment protocols the prognosis is often good. Primary psoas abscess has a better prognosis and lower mortality rates than secondary psoas abscess [7]. The major cause of death is delayed or inadequate therapy. Laboratory tests are helpful in the evaluation of suspected psoas abscess. Leucytosis (mean count, 15000/mm<sup>3</sup>), elevated erythrocyte sedimentation rate (ESR), elevated blood urea nitrogen (BUN) and liver enzymes were reported in the literature. Whenever a psoas abscess is suspected abdominal CT should be done since its diagnostic rates are 80% to 100% abdominal ultrasonography is diagnostic in only nearly half of the cases [4,8]. Magnetic resonance imaging (MRI) does not have an important role in the diagnosis of psoas abscess because the sensitivity and specificity of diagnosing psoas abscess is not improved by this radiologic method [4].

Treatment involves the use of early specific antibiotics, as well as drainage of the abscess. Knowledge of common pathogens should guide initial choice of antibiotics. Adjustments should be based on report of abscess fluid culture and sensitivity testing. Antistaphylococcal antibiotic therapy should be started before final bacteriologic diagnosis in cases of no other focus is detected and psoas abscess believed to be primary [9]. However,

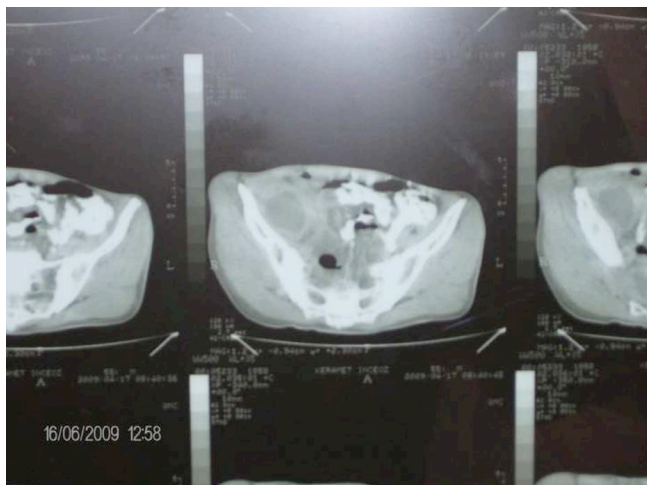


Figure 1. Computed tomography images demonstrate fluid collection in the right groin adjacent to the iliopsoas muscle

Table 1. Underlying diseases in patients with secondary psoas abscess

Gastrointestinal	Diverticulitis, appendicitis, Crohn's disease, Carcinoma of rectum colon, pancreatic abscess, appendiceal tumor, post appendectomy
Genitourinary	Urinary tract infection, perinepic abscess, extracorporeal shock wave lithotripsy,
Musculoskeletal	Lumbar infections, spondylodiskitis, infectious sacroiliitis, septic arthritis, Vertebral osteomyelitis
Other causes	Endocarditis, femoral artery catheterization, infected abdominal aortic aneurysm, hepatocellular carcinoma, trauma, intrauterine contraceptive device, foreign body reaction, suppurative adenitis, long-term dialysis

the identification of non-staphylococcus organisms in some patients with primary psoas abscess and the identification of staphylococcus in patients with secondary psoas abscess, to start treatment with broad spectrum antibiotics should be a rule. Clindamycin, antistaphylococcal penicillin, cephalosporin, aminoglycoside or metranidazole may be used for initial therapy.

Drainage of the abscess may be done through CT guided percutaneous drainage or surgical drainage. It can be said that percutaneous drainage is much less invasive and effective strategy for draining uniloculated psoas abscesses it is technically similar to open surgical drainage, and in many centers it has been advocated as the drainage method of first choice [10]. Surgical drainage is associated with shorter hospital stay and may be ideal for patients with multiloculated abscess and also with underlying gastrointestinal diseases like colitis ulserosa, Crohn's disease etc. In these patients, performing a single operation to drain abscess and resecting the diseased bowel may be an option [11]. An occasional patient may require multiple operations or repeated percutaneous drainage before the abscess resolves. Abscess drainage needs to be continued until obliteration of the abscess cavity occurs and there is evidence of clinical improvement. Parameters that can be used to determine clinical recovery include defervescence and normalization of the white blood cell count, as well as subjective improvement. The duration of antibiotic therapy should be individualized. In some cases multi-clinical approach and intervention may be essential in order to give the exact treatment.

#### References

1. Gruenwald I, Abrahamson J, Cohen O. Psoas abscess: case report and review of the literature. *J Urol* 1992;147:1624-1626.
2. Van den Berge M, De Marie S, Kuipers T, Jansz A.R., Bravenboer B. Psoas abscess: report of a series and review of the literature. *J Med* 2005;63:413-416.
3. Ataus S, Alan C, Önder A.U, Mihmanlı I, Talat Z, Yalçın V. Psoas abscess. *Cer-rahpasa J Med* 2000;31:89-93.
4. Taiwo B. Psoas abscess : A primer for the internist: Case Report. *South Med J* 2001;94:78- 80.
5. Santaella RO, Fishman EK, Lipsett PA. Primary versus secondary psoas abscess .Presentation microbiology and treatment. *Arch Surg* 1995;130:1309-13.
6. Harrigan RA, Kauffman FH, Love MB. Tuberculous psoas abscess. *J Emerg Med.* 1995;13(4):493-8.
7. Navarro Lopez V, Ramos JM, Meseguer V, Perez Arellano JL, Serrano R, García Ordonez. Microbiology and outcome of iliopsoas abscess in 124 patients. *Medicine (Baltimore).* 2009; 88:120-30.
8. Gruenwald I, Abrahamson J, Cohen O. Psoas abscess: case report and review of the literature. *J Urol* 1992;147:1624-1626.
9. Primary vs secondary iliopsoas abscess. Presentation, microbiology, and treatment. Santaella RO, Fishman EK, Lipsett PA. *Arch Surg.* 1995;130:1309-13.
10. Desandre AR, Cottone FJ, Evers ML. Iliopsoas abscess: etiology, diagnosis, and treatment. *Am Surg.* 1995;61:1087-91.
11. Veroux M, Angriman I, Ruffolo C, Fiamingo P, Caglià P, Madia C. Psoas abscess: a rare complication of Crohn's disease. *Acta Chir Belg.* 2004;104:187-90.